



**3M** Science.  
Applied to Life.™


3M Medical Securement Solutions

# The dirty truth about medical tapes.

Reducing the risk of cross-contamination.

# Dirty tapes could put your patients at risk.

Stocked in every supply room and brought to nearly every patient room, tape is one of the most widely-used medical technologies. 69% of clinicians use medical tape multiple times per day.<sup>1</sup> It holds breathing tubes in place, secures IV lines and manages post-operative drains, ports and other devices, and it comes into direct contact with patient skin. But are medical tapes clean or invisibly dirty?



## 100%

of tape rolls contaminated

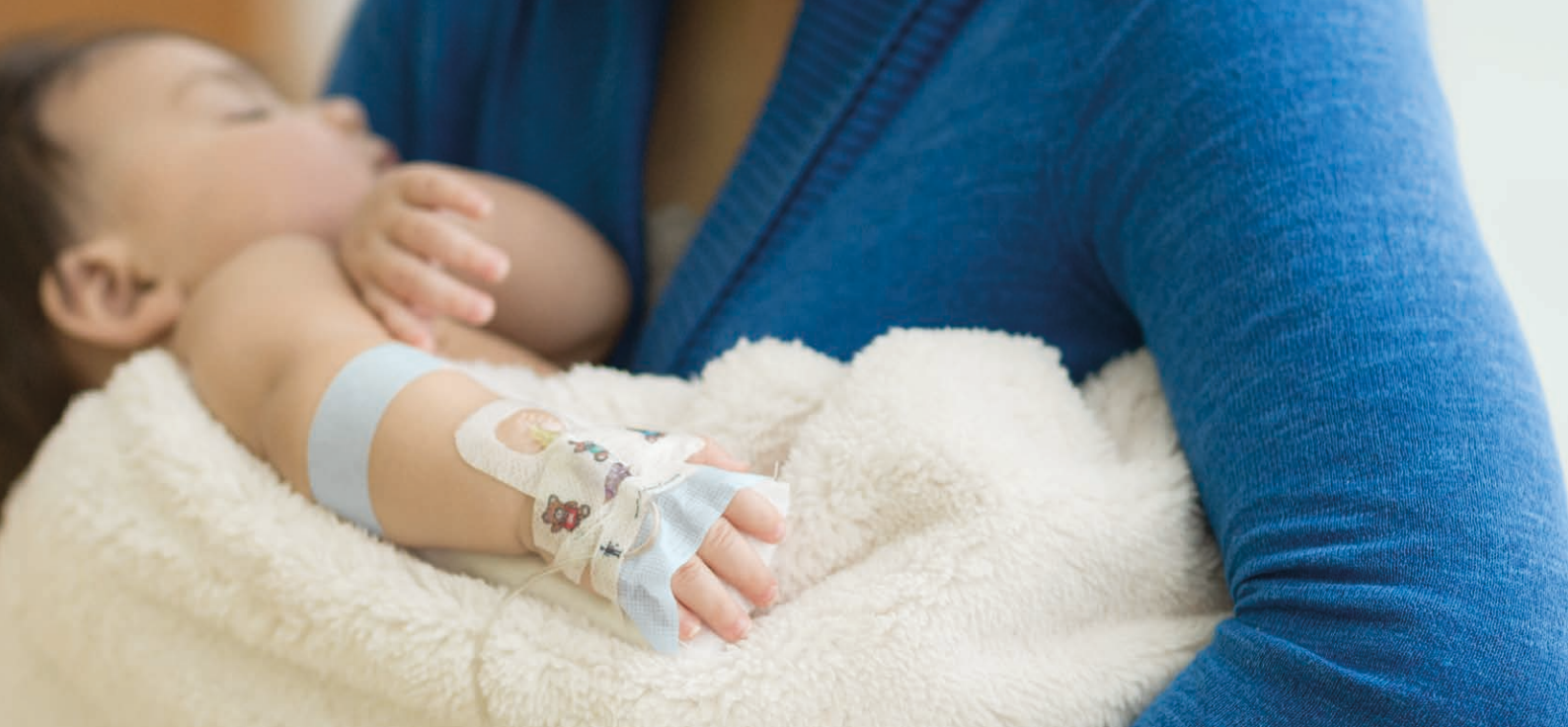A study sampled 24 bedside tape rolls at 1, 5 and 7 days in a 16-bed ICU at a 560-bed teaching hospital. 100% of the tape rolls sampled were contaminated.<sup>2</sup>



## 52%

of tape rolls contained MRSA and VRE

In one observation, 11 out of 21 tape samples used for multiple patients contained methicillin-resistant *Staphylococcus aureus* (MRSA) and/or vancomycin-resistant *enterococci* (VRE).<sup>3</sup>



## Why are tapes potential sources of contamination?

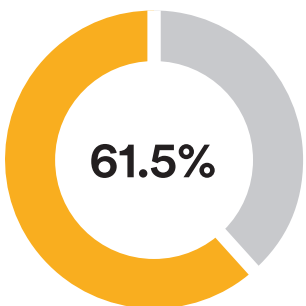
A survey by the *American Journal of Infection Control* showed that:



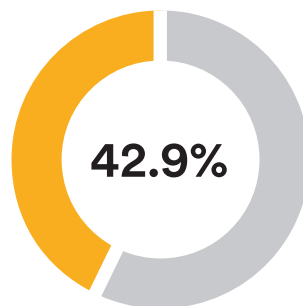
Multiple facilities had no existing policies or standards of care relating to tape storage and use.<sup>4</sup>



Tape was stored in open bins in clean supply rooms which were not regularly cleaned.<sup>4</sup>



61.5% of staff members carried rolls of tape in pockets or on stethoscopes.<sup>4</sup>



Only 42.9% of staff discarded unused tape when a patient was discharged.<sup>4</sup>

# The evidence is in: your tapes may be dirty.



**A 12 year old with relapsed acute myeloid leukemia contracted a suspected cutaneous fungal infection from tape exposure, which required three surgical debridements and a simple mastectomy.**

## **A gap in patient tape storage and use practices puts patients at risk for cutaneous fungal infections**

McClusky J, Davis M, Dahl K. *Am J Infect Control*. 2015;43(2):182-184.

### **Overview:**

This case report linked adhesive tape to a cutaneous fungal infection in a 12-year-old oncology patient at a facility with no established guidelines for patient tape. A subsequent survey of multiple healthcare facilities revealed no existing policies or standards of care related to tape storage or use.

### **Results:**

- A member of the Infectious Disease Department suspected that the cutaneous fungal infection was related to tape exposure.
- Three surgical debridements were required. Surgical cultures yielded *Mucor/Rhizopus*.
- Facilities stored tape in open bins in clean supply rooms, neither of which were regularly cleaned.
- There are zero guidelines from the Centers for Disease Control (CDC), Prevention Healthcare Infection Control Practices Advisory Committee, and the Association for Professionals in Infection Control and Epidemiology (APIC) for storage and use of tape.
- The gap in tape policies or standards calls for formal recommendations for storage and use to enhance patient safety.

### **View abstract:**

[https://www.ajicjournal.org/article/S0196-6553\(14\)01297-8/abstract](https://www.ajicjournal.org/article/S0196-6553(14)01297-8/abstract)



**The tapes found to be contaminated with *Zygomycosis* were removed and the cutaneous fungal outbreak subsided.**

## **Outbreak of cutaneous *Zygomycosis* associated with the use of adhesive tape in haematology patients**

Lalayanni C, Baliakas P, Xochelli A, et al. *J Hosp Infect.* 2012;81(3):213-215.

### **Overview:**


Case report of an outbreak of cutaneous *Rhizopus oryzae* infection associated with adhesive tapes used to stabilize peripheral venous catheters in four patients.

### **Results:**

- A recent review indicated that skin was the most commonly affected site in healthcare-associated *Mucormycosis* and patient mortality was high at 50%.
- The presenting sign appeared as itching erythema under the polyethylene adhesive that progressed to ulceration with necrosis.
- Although the particular tapes used in these patients were not tested, another tape of the same batch tested positive for *Zygomycete hyphae*.
- *In-vitro* cultures of adhesive tape scrapings consistently tested positive for *R. oryzae*.

### **View abstract:**

<https://www.ncbi.nlm.nih.gov/pubmed/22633275>



**Cutaneous *Mucormycosis* has been associated with the use of adhesive tape.**

## **Healthcare-associated *Mucormycosis***

Rammaert B, Lanternier F, Zahar JR, et al. *Clin Infect Dis.* 2012;54 Suppl 1:S44-54.

### **Overview:**

An extensive literature review analyzed the published evidence of 169 cases of *Mucormycosis* that occurred between 1970–2008.

### **Results:**

- The occurrence of *Mucormycosis* during healthcare procedures is not well documented and is probably underestimated.
- The literature review states: “*Mucormycosis* is a severe emerging invasive fungal infection that occurs as a consequence of environmental exposure with portals of entry including surgery and presence of medical devices such as catheters or adhesive tape.”

### **View abstract:**

<https://www.ncbi.nlm.nih.gov/pubmed/22247444>



**Molecular typing indicated that tape was the probable source of the infecting strain of *A. flavus* recovered from both infants.**

## **Use of a repetitive DNA Probe to type clinical and environmental isolates of *Aspergillus flavus* from a cluster of cutaneous infections in a neonatal intensive care unit**

James MJ, Lasker BA, McNeil MM, Shelton M, Warnock DW, Reiss E. *J Clin Microbiol.* 2000;38(10):3612-3618.

### **Overview:**

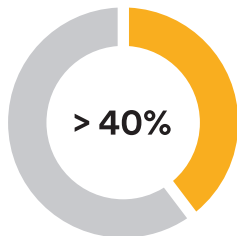This case study investigated two cases of cutaneous *A. flavus* infection in low-birth-weight (LBW) infants in a neonatal intensive care unit (NICU). Both infants were transported by the same ambulance and crew to the NICU on the same day and the same roll of tape was used to fasten their umbilical intravascular catheters.

### **Results:**

- Black abdominal skin lesions were found under adhesive tape used to fasten both infants' umbilical catheters. Culture resulted in an isolation consistent with an *Aspergillus* species.
- The roll of adhesive tape, a canvas bag used to store rolls of tape, the transport isolette, and a roll of clear plastic film all tested positive for *A. flavus*.
- Isolates obtained from both infants' abdominal lesions were indistinguishable from each other and identical to the isolates recovered from the roll of adhesive tape used.

### **View study:**

<https://www.ncbi.nlm.nih.gov/pmc/articles/PMC87445/>



**Tape can harbor pathogens more than 40% of the time despite efforts to clean the tape.**

## **Securing the endotracheal tube with adhesive tape: an integrative literature review**

Krug L, Machan M, Villalba J. *AANA J.* 2014;82(6):457-464.

### **Overview:**

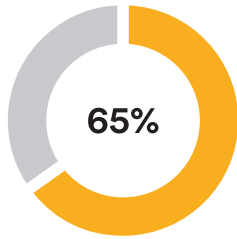
This literature review presents evidence-based research regarding endotracheal (ET) tube taping practice to ensure patient safety.

### **Results:**

- Overall, direction for the safe handling of surgical adhesive tape for patients is lacking.
- Normally, tape is not discarded at the end of a surgical case and is returned to the supply bin for use on other patients.
- An alternative tape would be short in length (30 in), have good adhesion, be disposable, and most importantly would be for single patient use and each tape roll would be individually packaged.

### **View abstract:**

<https://www.ncbi.nlm.nih.gov/pubmed/25842644>



**65% of sampled tapes left on shelves were colonized with *S. epidermidis*.**

## Sterility in unsterilized surgical adhesive tape

Bundy AT. *Plast Reconstr Surg.* 1989;83(5):880-883.

### Overview:

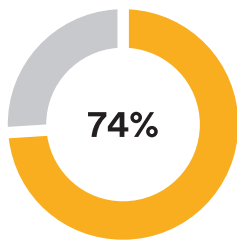
This study investigated the possibility that prepackaged unsterilized tape could be used to provide a barrier to infectious organisms.

### Results:

- 480 sliced samples from 120 rolls showed significant contamination of unpackaged tapes left on the shelf of a surgical suite cabinet for two weeks.
- The two sample brands tested showed significant values ( $p < 0.01$ ) for contamination on the smooth outer revolution and edge of the rolls.
- The study concluded that prepackaged surgical adhesive tape can be used to approximate wound edges without being a source of contamination.

### View abstract:

[https://journals.lww.com/plasrecon surg/Citation/1989/05000/Sterility\\_in\\_Unsterilized\\_Surgical\\_Adhesive\\_Tape.19.aspx](https://journals.lww.com/plasrecon surg/Citation/1989/05000/Sterility_in_Unsterilized_Surgical_Adhesive_Tape.19.aspx)



**74% of partially used tape rolls contained some bacterial growth.**

## Adhesive tape and intravascular-catheter-associated infections

Redelmeier D, Livesley N. *J Gen Intern Med.* 1999;14(6):373-375.

### Overview:

The object of the study was to determine whether a roll of adhesive tape can become colonized by organisms and contribute to intravascular catheter infections. 80 rolls of adhesive tape were collected from sites around a hospital over a two-week period and evaluated for rates of contamination.

### Results:

- Tape is often found in clinicians' pockets, in drawers, on counters or hanging from stethoscopes or IV poles.
- Tape from the inner layer showed fewer colony formations (2 of 42 specimens) compared with the outer layer (59 of 80 specimens). Adhesive tape may transmit pathogenic bacteria that contribute to infections.
- Switching to shorter rolls of medical tapes can provide an important opportunity to decrease cross-contamination.

### View study:

[https://www.ncbi.nlm.nih.gov/pmc/articles/PMC1496597/pdf/jgi\\_355.pdf](https://www.ncbi.nlm.nih.gov/pmc/articles/PMC1496597/pdf/jgi_355.pdf)



# Help reduce the risk of cross-contamination with individually packaged single-patient-use rolls.\*



## 3M™ Micropore™ S Surgical Tape

Clinical applications such as:

- Blood draws
- Light-weight dressings
- IV lines and tubing (secondary securement)
- Non-critical tubes

Catalog #	Size	Rolls	Case
2770S-1	2,5 cm x 1,3 m	100 per bag	5 bags
2770S-2	5 cm x 1,3 m	50 per bag	5 bags



## 3M™ Medipore™ H Soft Cloth Surgical Tape

Clinical applications such as:

- Dressings and added pressure
- IV lines and tubing (secondary securement)
- When swelling or movement is anticipated
- Central venous catheters (secondary securement)
- Chest tubes
- Surgical drain tubes

Catalog #	Size	Rolls	Case
2860S-1	2,5 cm x 1,8 m	72 per bag	1 bag
2860S-2	5 cm x 1,8 m	48 per bag	1 bag
2860S-4	10,1 cm x 1,8 m	24 per bag	1 bag
2860S-6	15,2 cm x 1,8 m	16 per bag	1 bag



## 3M™ Durapore™ Surgical Tape

Clinical applications such as:

- Urinary catheters
- Nasogastric tubes
- Orogastric tubes
- Patient positioning
- Short-term securement of endotracheal tubes
- For use in dry conditions\*\*

\*\* Not recommended for use when excessive fluids and/or secretions are present. Tape securement and tube position should be monitored routinely.

Catalog #	Size	Rolls	Case
1548S-1	2,5 cm x 1,37 m	100 per bag	1 bag
1548S-2	5 cm x 1,37 m	50 per bag	1 bag



## 3M™ Coban™ NL Non-Latex Self-Adherent Wrap

Clinical applications such as:

- Blood draws
- Dressings
- Immobilization
- Securement for difficult to dress areas (head, fingers, toes)
- Support and mild compression for soft tissue injuries (e.g. strains, sprains)\*\*\*

\*\*\* May be used as a component of a compression system under the direction of a health care professional.

Catalog #	Size	Rolls
2082-1X	50 mm x 0,6 m	36 per bag
	50 mm x 1,5 m	
2084-1X	100 mm x 0,6 m	18 per bag
	100 mm x 1,5 m	

\* Individually packaged, single-patient-use rolls help prevent tape from being exposed to environmental contaminants, minimize contact with hospital surfaces and equipment, and minimize exposure to healthcare worker hands.

- 3M 2018 Medical Tape Market Research. On file at 3M.
- Berkowitz DM, Lee WS, Pazin GJ, Yee RB, Ho M. Adhesive Tape: Potential Source of Nosocomial Bacteria. *Appl Microbiol.* 1974;28(4):651-654.
- Harris PN, Ashhurst-Smith C, Berenger SJ, Shoober A, Ferguson JK. Adhesive tape in the health care setting: another high-risk fomite? *Med J Aust.* 2012;196(1):34.
- McClusky J, Davis M, Dahl K. A gap in patient tape storage and use practices puts patients at risk for cutaneous fungal infections. *Am J Infect Control.* 2015;43(2):182-184.



**3M United Kingdom PLC**  
 Charnwood Campus  
 10 Bakewell Road  
 Loughborough  
 Leicestershire LE11 5RB  
 +44 (0)1509 611 611

**3M Ireland Limited**  
 The Iveagh Building,  
 The Park, Carrickmines,  
 D18 X015  
 Ireland  
 +353 (0)1 280 3555

3M, Coban, Medipore and Micropore are marks and/or registered marks of 3M. Please recycle.  
 © 3M 2020. All rights reserved.  
 70-2011-7933-3